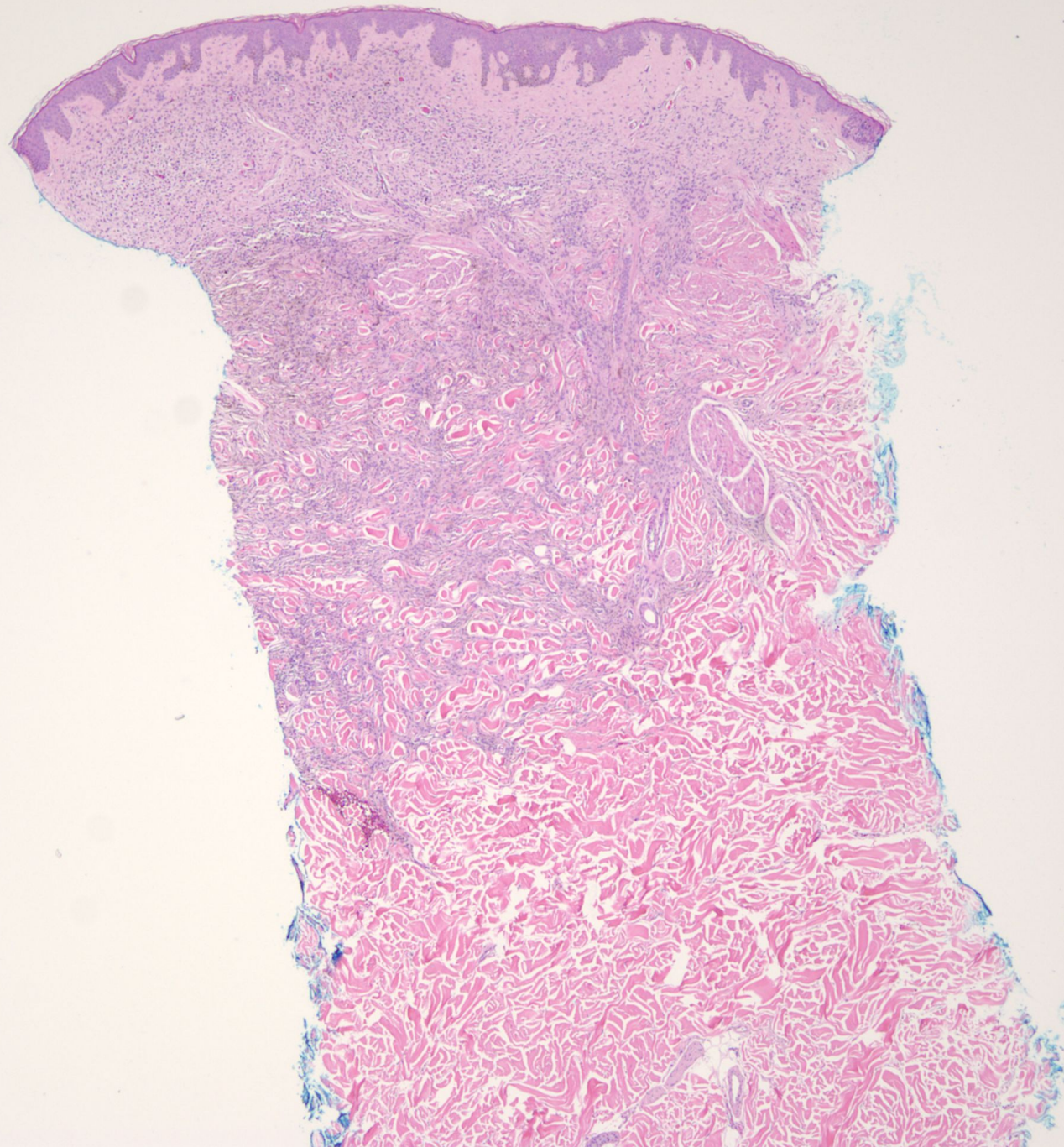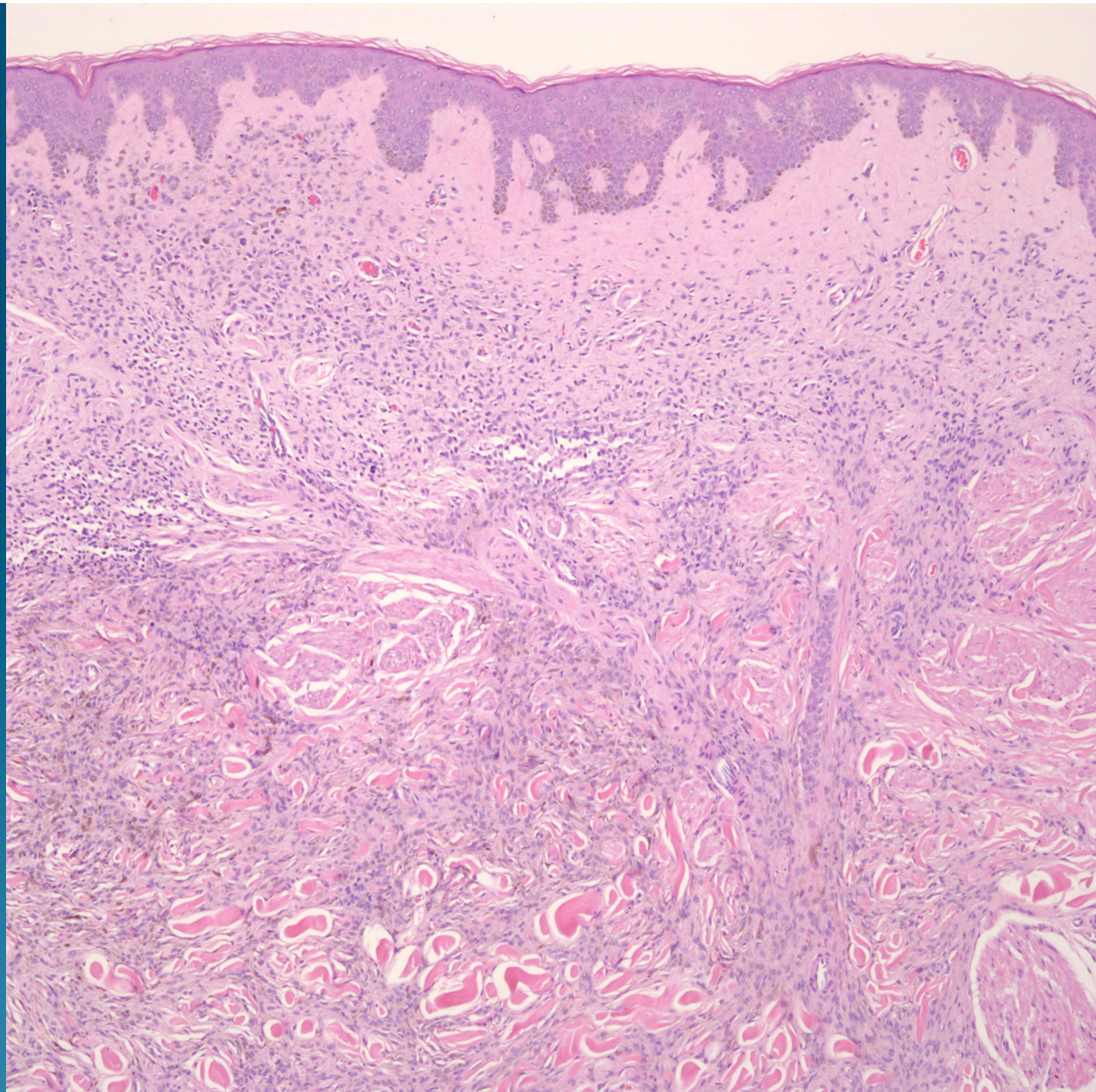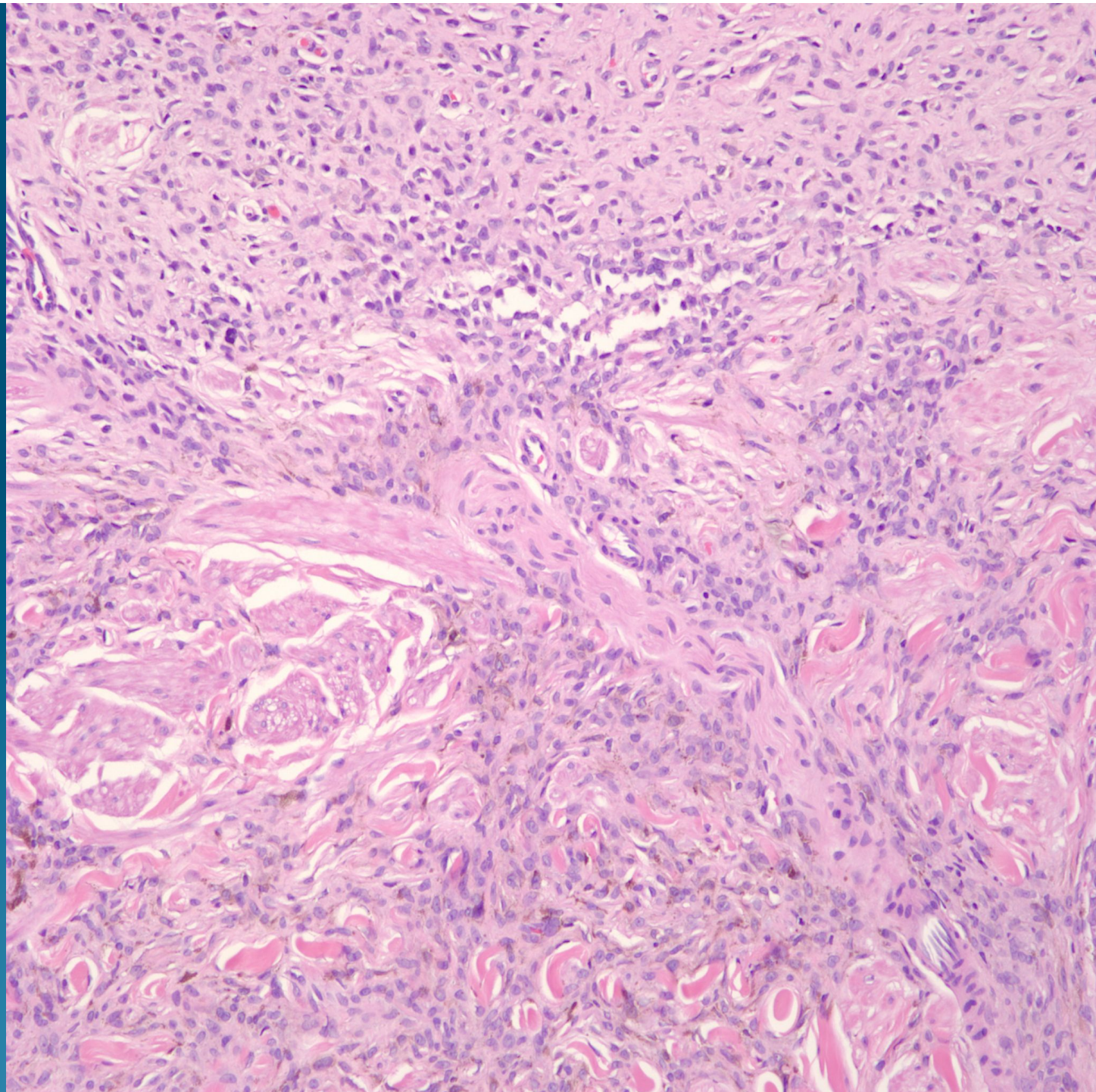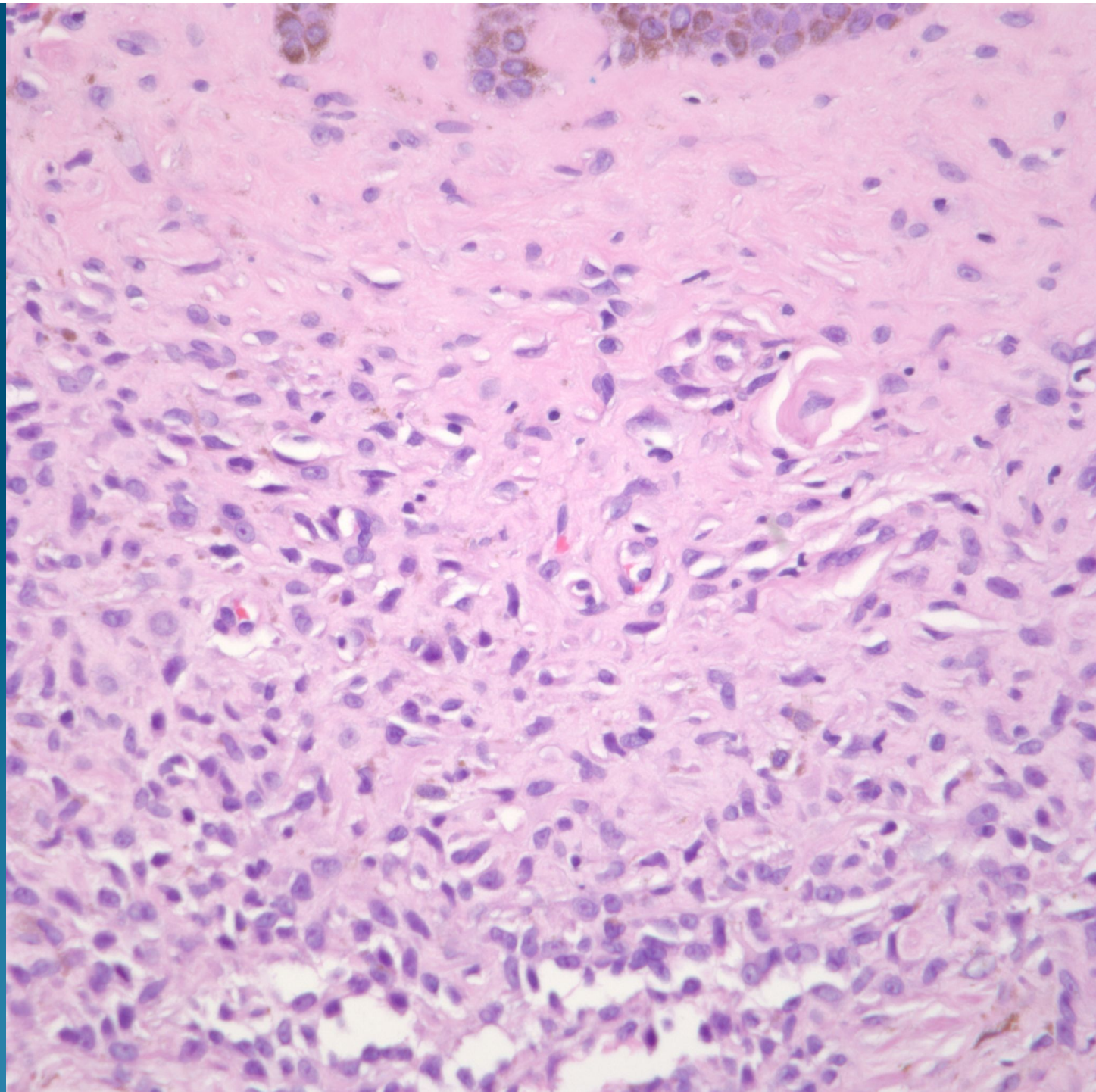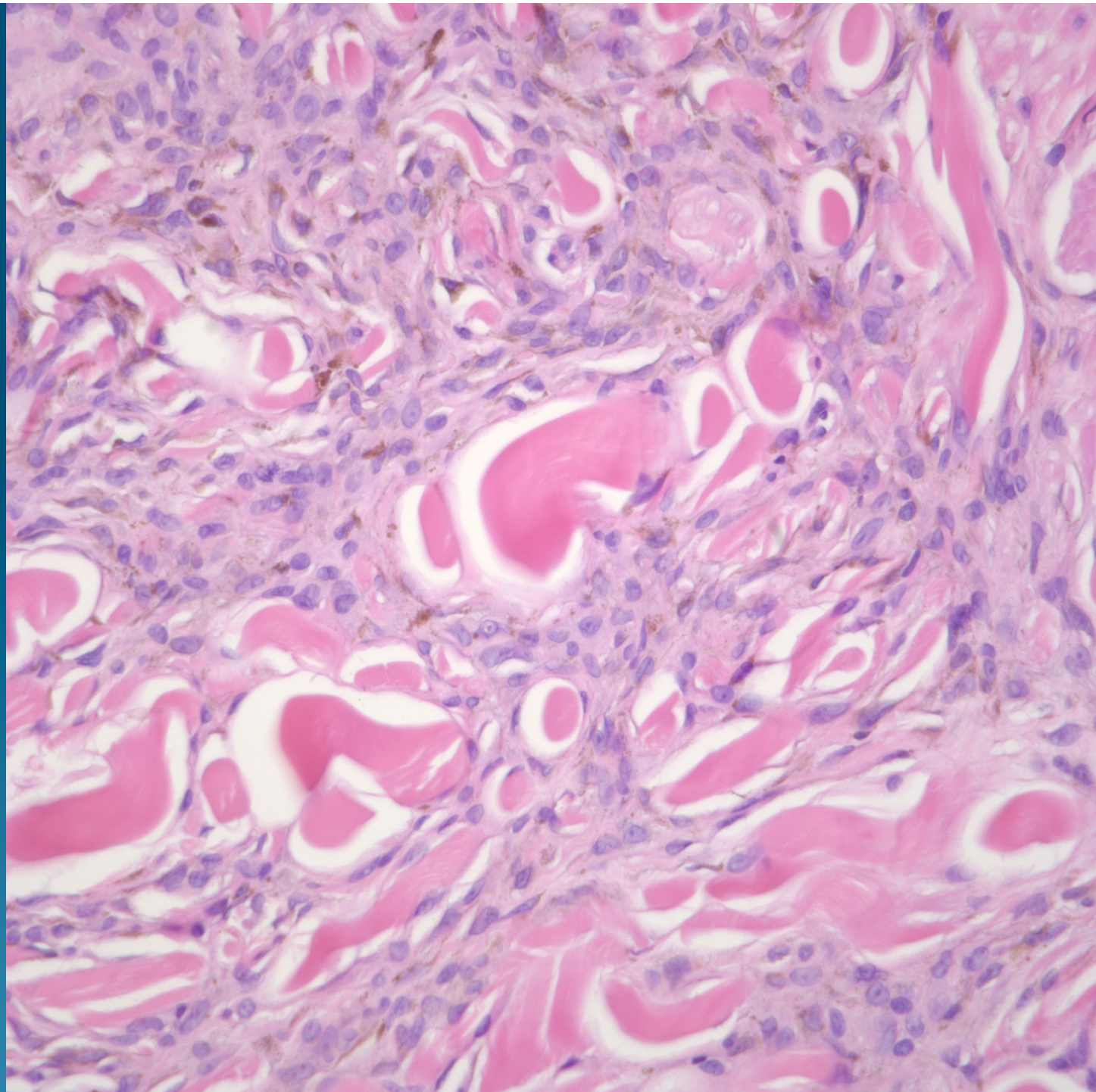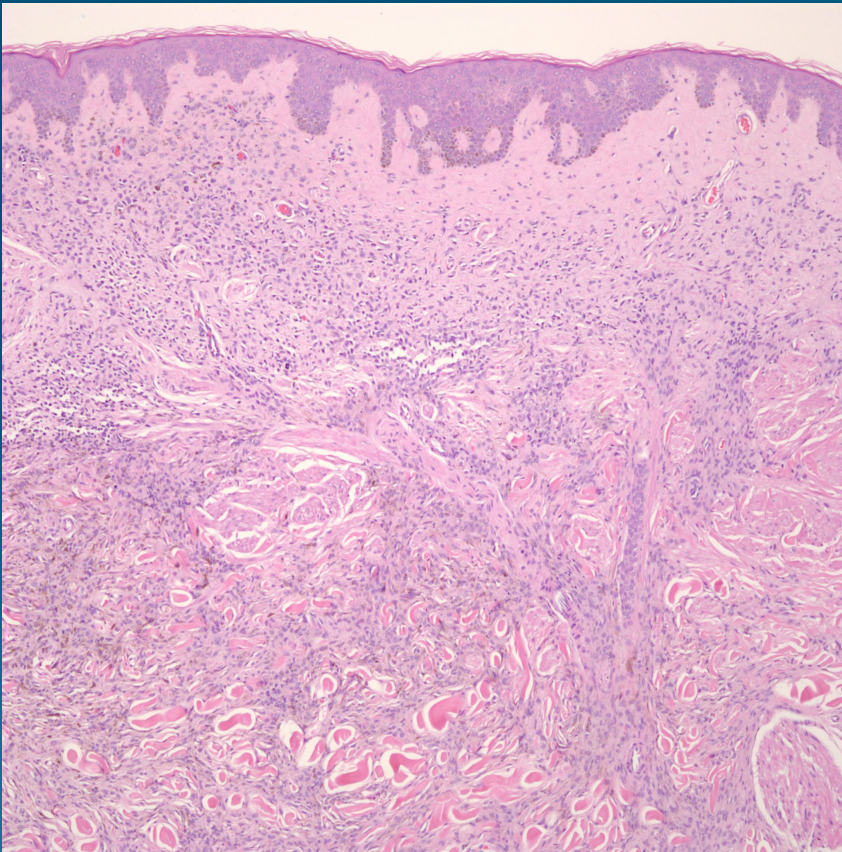


Combined Melanocytic Nevus (Intradermal nevus and blue nevus)

Pearls



- Combined refers to conventional melanocytic nevus arising with other acquired or congenital nevus
- Melanocytes may merge
- Clinically and histologically heterogeneous